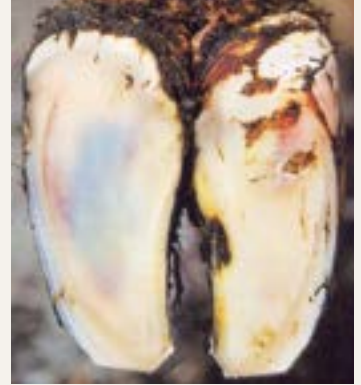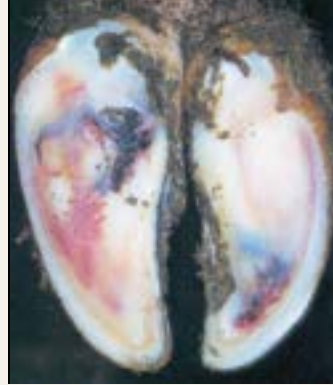


Prevention of sub-clinical laminitis

Sub-clinical laminitis is the most frequent laminitis form in dairy cattle. Although affected animals are not clearly lame at first, sub-clinical laminitis causes a multitude of economically significant claw diseases.



Blueish or yellow-red colourings are typical signs of sub-clinical laminitis.

Function of the corium

A healthy corium supports the claw bone and holds it in place. If it is weakened, e.g. due to a lack of oxygen and nutrients, it loses its function and the claw bone can "rotate" or even sink in the horny shoe.

Bergsten, 2003

A precursor to many complications

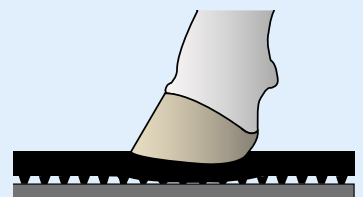
What is clear is that metabolic disorders weaken the corium. Hard floors and misalignments of the claw can lead to pressure peaks. The additional mechanical load favours punctual bruising of the weakened corium. This is considered a cause of secondary claw diseases like sole ulcers, double sole or white line disease. The defects often arise where the corium has been bruised by the claw bone - comparable to an "imprint" of the claw bone on the sole.

Fürll et al., 2011; Bergsten, 2003

KRAIBURG KURA - soft flooring as a preventive

Rubber flooring has a positive effect in cases of sub-clinical laminitis. Soft flooring relieves pressure and reduces punctual bruising of the weakened corium. The affected animals can also move without pain and will walk towards feed more often - which is important for healthy metabolism and claws!

Fürll et al., 2011; Bergsten, 2003



Images: Landwirtschaftsverlag GmbH, 2003

